

Contralateral Lateral Femoral Condyle Allografts Provide an Acceptable Surface Match for Simulated Osteochondritis Dissecans Lesions of the Medial Femoral Condyle

Nabeel Salka, MSE & John A. Grant, MD, PhD, FRCSC

**MedSport, Department of Orthopedic Surgery
University of Michigan, Ann Arbor, MI**

Financial Disclosure: This study was funded by JRF Ortho

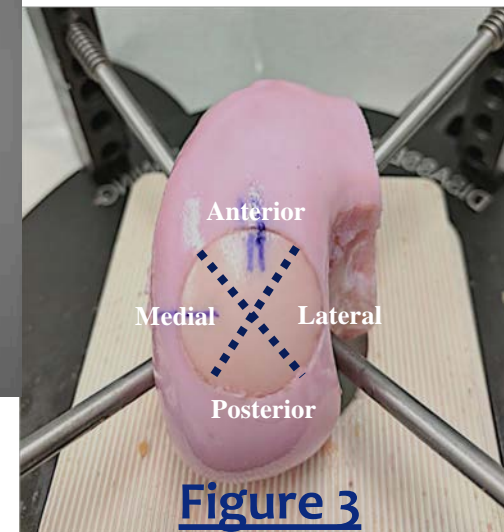
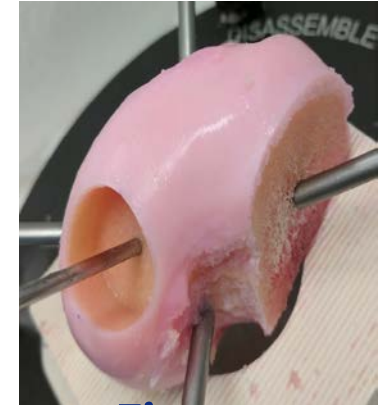
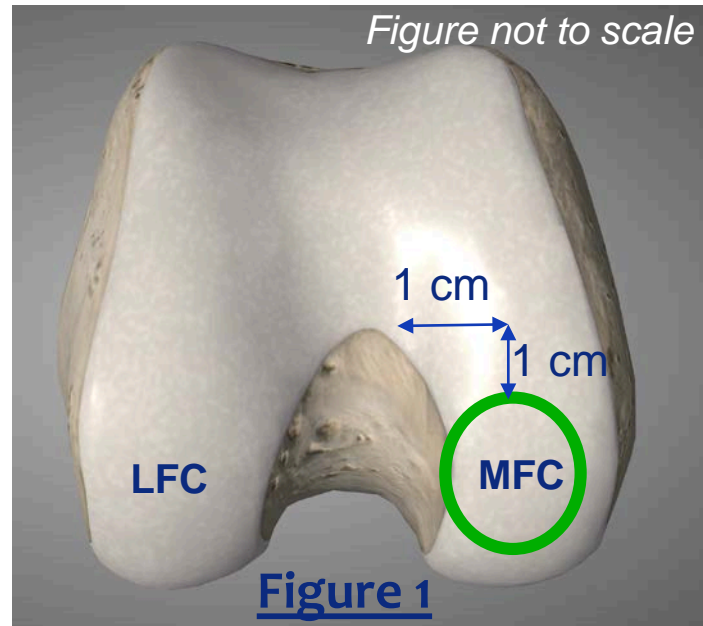
Purpose

- Osteochondritis dissecans (OCD) of the knee is a common musculoskeletal injury in young active patients characterized by the separation of cartilage and subchondral bone from the surrounding bone.[1]
- Osteochondral allograft transplant is an effective treatment for large unreparable lesions. [2]
- 70% of allograft requests are for medial femoral condyles (MFC) while there are ~25% more LFC grafts available for use.
- Prior work has found that contralateral LFC allografts provide an acceptable geometric match to the native MFC (within 1mm proud/sunken) [4].
- An acceptable geometric match has been linked to restoration of physiologic contact stresses at the joint. [5]
- Current models of osteochondral damage, however, position the defect at the center of the condyle, whereas the “classic” OCD lesion (70% of cases) is on the posterolateral region of the MFC where the condylar curvature abruptly changes. [6]
- **Study Objective:** To determine whether any difference exists in the ability of location-matched ipsilateral MFC and contralateral LFC allografts to match the surface geometry of the native MFC in the classic OCD lesion location.

Methods and Materials

Ten groups of size-matched cadaveric recipient MFC, donor MFC, donor LFC (IRB exempt)

1. Mark location of the 20mm “defect” in recipient condyle (**Fig. 1**)
2. Nano-CT scan recipient condyle
3. Create 20mm osteochondral defect socket (**Fig. 2**)
4. Harvest allograft plug from randomly selected size-matched donor (MFC/LFC)
5. Trim allograft plug to fit socket
6. Press-fit allograft (**Fig. 3**)
7. Nano-CT scan with allograft
8. Repeat the process for the other allograft



Step-Off Height Analysis

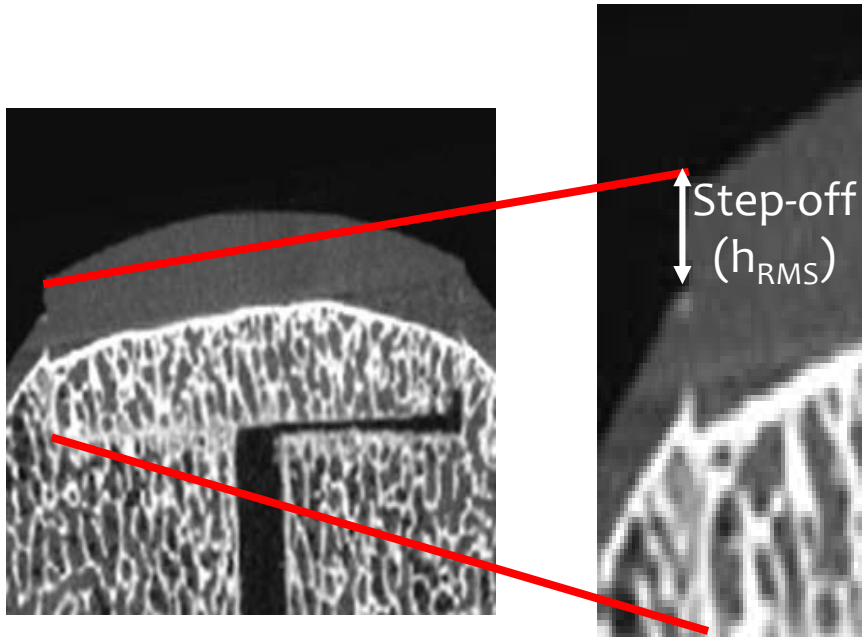


Figure 4

Surface Deviation (d_{RMS})

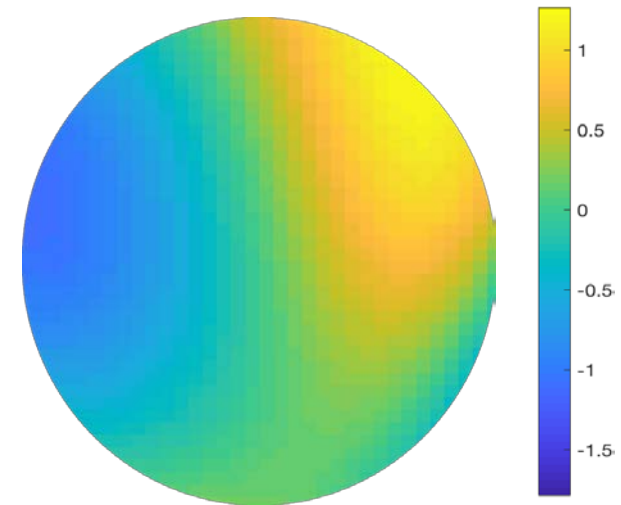
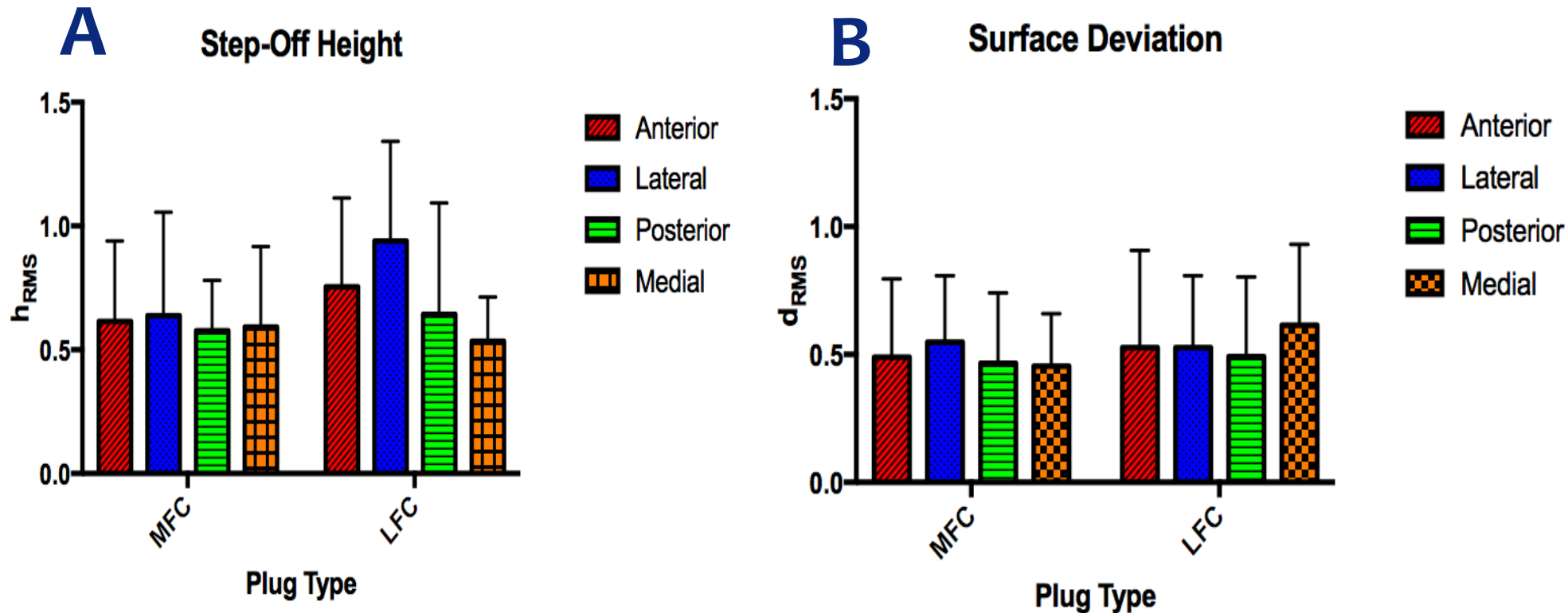


Figure 5: Regions of the plug elevated relative to the native surface are in yellow, flush regions are in green, sunken regions are in blue

- Circumferential step-off height (allograft vs surrounding native cartilage at 3° increments, in mm; **Fig. 4**), and surface height deviations (allograft vs native cartilage surface, in mm at ~ 3000 surface points; **Fig. 5**) were measured
 - Reported as the root mean squared (h_{RMS} , d_{RMS}) value to negate offsetting measures of proud and sunken areas.
- %Circumference ($\%C_{proud}$, $\%C_{sunken}$) and %Area ($\%A_{proud}$, $\%A_{sunken}$) proud and sunken were also calculated for each quadrant
 - Deviations of ≤ 1 mm were deemed acceptable.

Results

Figure 6: (A) Step-off height (h_{RMS} , mm) and (B) surface deviation (d_{RMS} , mm) were not significantly affected by plug type or location.



Results

- Lateral quadrant of the LFC was more proud than all other quadrants (* is significantly different from ^t)
- No differences between MFC and LFC in %C_{sunk}, %A_{proud}, %A_{sunk}.
 - Data presented as mean ± SD (mm)

	MFC					LFC				
	Anterior	Medial	Posterior	Lateral	Total	Anterior	Medial	Posterior	Lateral	Total
%C _{proud}	0.00 ± 0.00	0.00 ± 0.00	1.67 ± 5.27	11.3 ± 27.0	2.42 ± 7.64	2.00 ± 5.26 ^t	1.33 ± 4.22 ^t	0.00 ± 0.00 ^t	28.0 ± 26.1*	8.08 ± 6.89
%C _{sunk}	18.0 ± 27.9	17.7 ± 31.9	7.00 ± 15.3	11.0 ± 24.7	13.4 ± 17.9	26.0 ± 33.1	3.67 ± 7.77	16.7 ± 36.0	4.67 ± 7.06	13.2 ± 14.5
%A _{proud}	4.38 ± 13.2	0.00 ± 0.00	0.00 ± 0.00	7.12 ± 11.8	3.16 ± 5.28	2.21 ± 4.52	15.1 ± 23.1	3.88 ± 11.7	5.06 ± 15.2	6.12 ± 10.6
%A _{sunk}	2.42 ± 7.25	2.20 ± 5.96	9.41 ± 28.2	1.32 ± 3.97	3.63 ± 7.94	9.48 ± 28.1	2.11 ± 4.82	10.1 ± 30.2	5.18 ± 10.5	6.08 ± 12.1

Results – Surface Height Deviation Maps

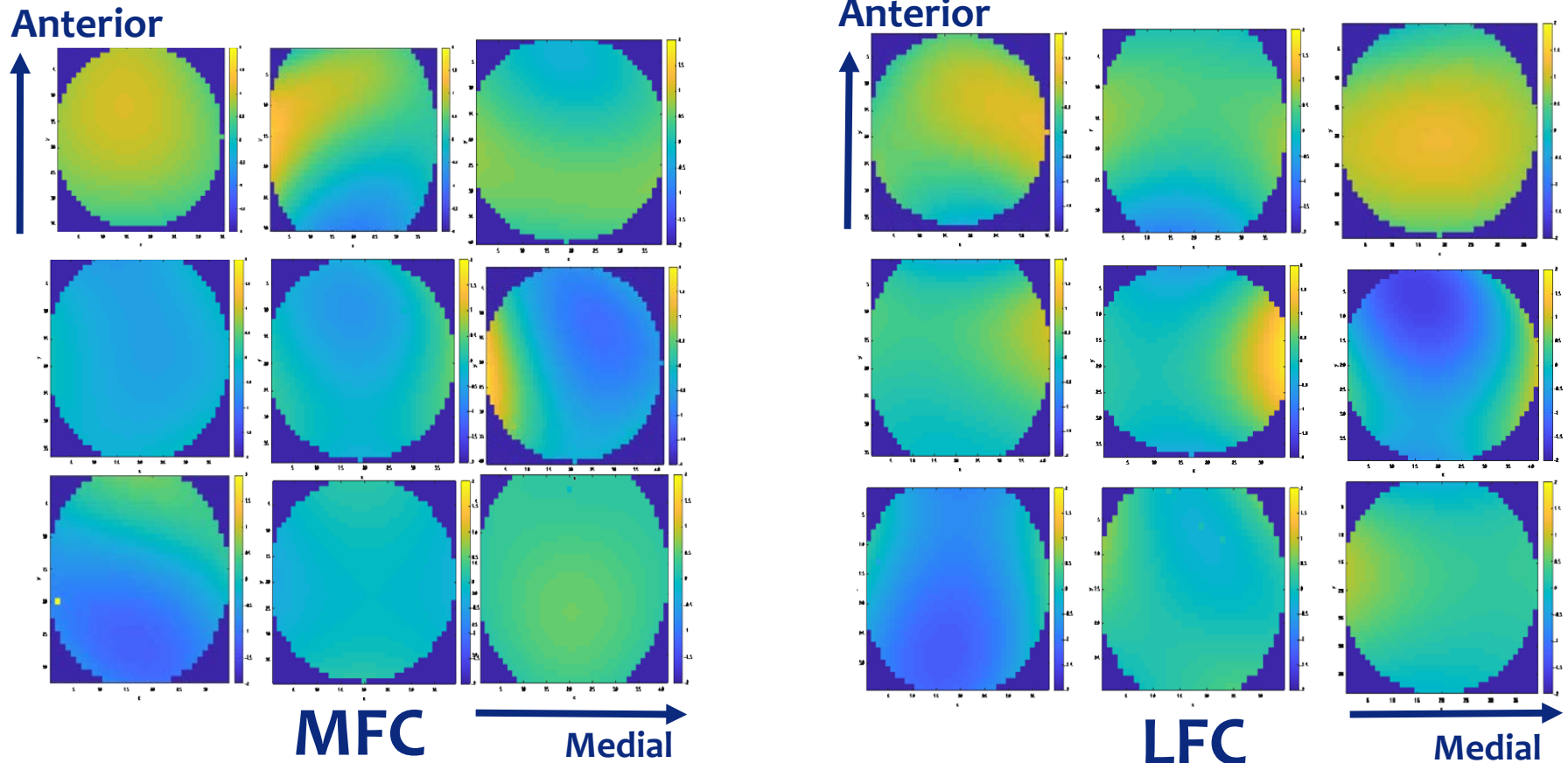


Figure 7: 9 subject groups; yellow indicates regions of plug elevation (>1mm) relative to the native condyle, green is flush, and blue indicates regions where the plug is sunken (>1mm) relative to the native condyle.

Conclusions

- No differences in h_{RMS} and d_{RMS} between MFC and LFC allografts
 - No difference in the overall average circumferential step-off height or the overall surface height deviation between MFC and LFC allografts
 - Suggests that contralateral LFC allografts can be as effective as ipsilateral MFC allografts in replicating the surface geometry of the native MFC at the classic site of OCD lesions.
- Significantly elevated $\%C_{proud}$ in the lateral quadrant of LFC, but not MFC allografts, occurred despite similar average curvature between MFC and LFC condyles [7].
- Significance: The acceptable surface match of LFC allografts to the native MFC surface at the “classic” site of OCD lesions helps address concerns of donor tissue availability when treating these osteochondral lesions.

References

- [1] Hughston JC, Hergenroeder PT, Courtenay BG. Osteochondritis dissecans of the femoral condyles. JBJS. 1984;66A(9): 1340-1348.
- [2] Sadr, KN, Pulido, P, McCauley, JC, & Bugbee, W. Fresh osteochondral allograft transplantation for osteochondritis dissecans of the knee. Orthopaedic J Sports Med. 2014; 2(1 suppl), 2325967114S00001.
- [3] McCulloch PC, Kang RW, Sobhy MH, Hayden JK, Cole BJ. Prospective evaluation of prolonged fresh osteochondral allograft transplantation of the femoral condyle: Minimum 2-year follow-up. Am J Sports Med. 2007;35(3):411-420.
- [4] Mologne TS, Cory E, Hansen BC, et al. Osteochondral allograft transplant to the medial femoral condyle using a medial or lateral femoral condyle allograft: Is there a difference in graft sources? Am J Sports Med. 2014;42(9):2205-2213.
- [5] Koh JL, Wirsing K, Lautenschlager E, Zhang LO. The effect of graft height mismatch on contact pressure following osteochondral grafting: A biomechanical study. Am J Sports Med. 2004;32(2):317-320.
- [6] Kocher MS, Tucker R, Ganley TJ, Flynn JM. Management of osteochondritis dissecans of the knee: Current concepts review. Am J Sports Med. 2006;34(7):1181-1191.
- [7] Hohe J, Ateshian G, Reiser M, Englmeier KH, Eckstein F. Surface size, curvature analysis, and assessment of knee joint incongruity with MRI in vivo. Magn Reson Med. 2002;47(3):554-561.
- **We would like to thank Andrea Clark, Ranae Hoeft, and Jaron Scott for their contributions.**
- **This study was funded by JRF Ortho**